

## Pulsed Magnetic Fields Applied to a Transferred Arterial Loop Support the Rat Groin Composite Flap

Renata V. Weber, M.D., Alberto Navarro, M.D., June K. Wu, M.D., Han-Liang Yu, M.D., and Berish Strauch, M.D.

Bronx, N.Y.

Pulsed magnetic fields have been shown to stimulate neovascularization in the authors' laboratory. The rat groin composite flap was used to create a prospective randomized trial to test the effectiveness of these pulsed magnetic fields. The skin paddle to this flap is highly consistent, and the authors proposed using the flap to study how pulsed magnetic fields affect composite flap survival when the dominant vessel to the flap is divided and flap survival becomes dependent on a transferred vessel loop. Forty-three rats had the tail artery microsurgically anastomosed to the femoral artery and placed between the groin musculature and the abdominal skin. Pulsed magnetic energy of 1 gauss was applied for 8 ( $n = 14$ ) or 12 ( $n = 8$ ) weeks to the experimental groups. Control groups were treated in a comparable manner for 8 ( $n = 16$ ) or 12 ( $n = 5$ ) weeks. After the 8 or 12 weeks, all groups had an  $8 \times 4$ -cm skin flap raised, and the superficial epigastric artery, the main feeding vessel, was ligated. After 5 days, the total area of the flap and the area of necrosis were traced onto velum paper for each rat. The percent survival was calculated per rat, and a mean survival percentage was calculated per group. The experimental animals treated with pulsed magnetic fields for 8 weeks had statistically significant improved flap survival over the control animals. The study provides evidence that pulsed magnetic energy stimulates angiogenesis and suggests a possible use of this modality to create island vascular flaps in otherwise random vascular territories. (*Plast. Reconstr. Surg.* 114: 1185, 2004.)

Research on pulsed magnetic fields and their effect on soft-tissue injury and bone healing has been studied in some detail over the last decade. Glazer et al.<sup>1</sup> observed that the use of electromagnetic field therapy in a rabbit spinal-fusion model increased bone rigidity and achieved increased load to stress. Its effect on resistant fracture nonunions is to signifi-

cantly reduce the time required for bony union to occur.<sup>2</sup> In fact, Darendeliler et al.<sup>3</sup> showed that even static magnetic fields seem to accelerate the rate of bone repair compared with control groups.

The reason for accelerated healing of bone after pulsed magnetic field energy has not been explained. Even less is known about its effect on blood vessels. Some researchers<sup>4,5</sup> theorize that pulsed magnetic energy may act at the cellular level by changing the cellular plasma membrane potential, encouraging a calcium flux that may stimulate a cellular response. It has been shown that the type of pulsed waveform applied affects cells differently in vitro. The pulsed burst waveform stimulates blood vessel creation, whereas the single pulsed waveform influences maturation but not the rate of vascular growth.<sup>6</sup> The actual mechanism by which pulsed magnetic fields stimulate angiogenesis is still poorly understood.

Our laboratory previously demonstrated<sup>7</sup> that pulsed magnetic energy, when applied to a microsurgically transferred arterial vessel loop, produced a time-dependent increase in neovascularization. We devised an experiment using the well-established and reliable model of the rat groin composite flap.<sup>8</sup> On the observation that pulsed magnetic field energy stimulates angiogenesis, we created a randomized prospective study to evaluate the effect of pulsed magnetic fields on groin composite flap survival when the dominant vessel to this flap is

From the Department of Plastic and Reconstructive Surgery, Albert Einstein College of Medicine and Montefiore Medical Center. Received for publication March 31, 2003; revised October 17, 2003.

DOI: 10.1097/01.PRS.0000135857.95310.13

divided and graft survival becomes dependent on a transferred vessel loop.

#### MATERIALS AND METHODS

Adult male Sprague-Dawley rats (325 to 350 g) were obtained and placed two per cage in the vivarium with a constant 12-hour cycle of light/darkness. Each rat was allowed to acclimatize. The average weight at the time of the first surgical procedure was  $370 \pm 43$  g. Each rat underwent two operative procedures, and the four groups of animals were handled in a comparable manner. The animals were placed into one of four groups: group 1 ( $n = 16$ ) was the control to group 2 ( $n = 14$ ), which would receive 8 weeks of pulsed magnetic energy therapy. Group 3 ( $n = 5$ ) was the control to group 4 ( $n = 8$ ), which would receive 12 weeks of pulsed magnetic energy therapy.

##### *First Operative Procedure: Creating the Transferred Arterial Loop*

All animals were anesthetized with a mixture of MetaMine/medetomidine (Silicon Genetics, Redwood City, Calif.) 75/0.5 mg/kg intraperitoneally in accordance with the animal care protocol. Using sterile surgical techniques, each animal had a 12- to 14-cm segment of tail artery harvested using microsurgical technique. The artery was flushed and then placed in a heparinized saline solution (60 U/ml), and the tail was sutured using 4-0 Ethilon. Under a Zeiss operating microscope, each rat tail artery was anastomosed as an interposition vascular graft using 10-0 Ethilon interrupted sutures to the femoral artery proximal to the superficial inferior epigastric artery. In all instances, the same experienced investigators performed all end-to-end anastomoses.

The resulting loop was then placed in a pocket created over the animal's abdominal wall and under the skin complex. The groin incision was closed with running 4-0 Ethilon. Each animal was randomly placed into one of four groups as described. Control groups were handled but not treated with pulsed magnetic fields for 8 or 12 weeks, and the experimental groups were exposed to pulsed magnetic fields for 8 or 12 weeks. For 5 days postoperatively, the animals received analgesic in their drinking water (acetaminophen 1.3 mg/cc, with an average consumption of 35 to 40 cc/day), and were checked twice daily for wound dehiscence and infection. Food and water were provided ad libitum.

##### *Application of Pulsed Magnetic Fields*

One 30-minute session was given immediately postoperatively to the experimental animals. Starting the next day, the experimental animals received two 30-minute sessions of pulsed magnetic field treatments using the MRT *sofPulse* (Electropharmacology, Inc., Pompano, FL). Daily sessions were a minimum of 4 hours apart. The dose used was a 65- $\mu$ sec burst of 27.12-MHz sinusoidal waves at 1-gauss amplitude repeated at 600/second. This dosing regimen had been used previously without noticeable adverse effects on the animals and was as effective in promoting angiogenesis as the higher dose of 2 gauss.<sup>7</sup> Animals were positioned on top of the applicator head and confined to insure that treatment was properly applied.

##### *Second Operative Procedure: Creating the Composite Flap*

After either 8 or 12 weeks, the rats were re-anesthetized for the second procedure with ketamine/medetomidine 75/0.5 mg/kg intraperitoneally again in accordance with the animal care protocol. After adequate anesthesia had been achieved, the right groin was shaved and prepped with Betadine/alcohol solution using sterile techniques. Using sharp surgical dissection, a skin flap measuring 8 cm long  $\times$  4 cm wide was raised on the right side of the animal, incorporating the vessel loop and its tributaries within the composite flap. The patency of the femoral artery and arterial loop were checked in all cases. Animals with patent arterial interposition grafts were included in the experiment.

The composite flap was raised off the underlying musculature, based on the superficial inferior epigastric artery and vein and on the neoarterial loop. Once elevated the superficial inferior epigastric artery was ligated (Fig. 1) and the composite flap was resutured in place with 4-0 Ethilon. At this stage, the entire arterial inflow was supplied by the transferred arterial loop and the venous drainage was through the superficial inferior epigastric vein. For the 5 postoperative days, food and water was provided ad libitum and the animals received analgesic in their drinking water as before. The animals were checked twice daily for wound dehiscence, infection, and evidence of survival or necrosis of the flap. On postoperative day 5, the animals were euthanized and the total area of each flap and the areas of necrosis

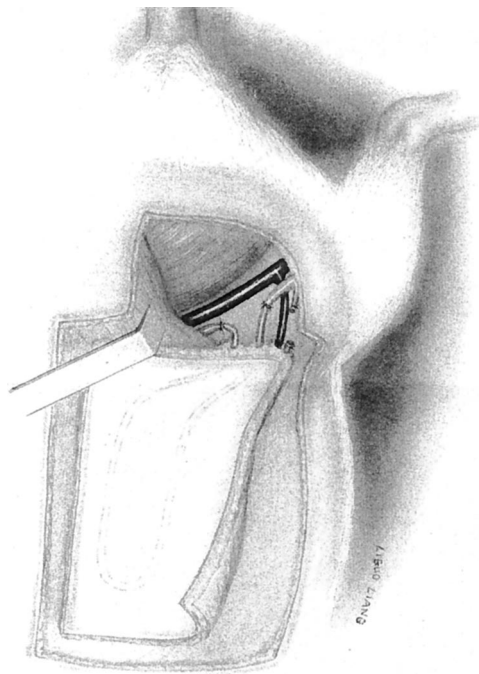


FIG. 1. Line drawing of the second experimental procedure. The composite flap is shown elevated on the rat tail artery that had been placed end to end between the divided femoral artery. The superficial epigastric artery is shown divided.

were traced onto velum paper. Flap creation and evaluation at death were done by the same investigators, and the randomly renumbered tracings were evaluated by an independent investigator.

#### Flap Analysis

The tracings were scanned and analyzed using NIH Image 1.62 (National Institutes of Health, Washington, D.C.). A percentage of flap survival for each animal was calculated as the viable area of flap over the total area of flap at the time of death. The flap survival percentages were averaged for the four groups, and these averages were compared for statistical significance. Two animals per group were randomly selected for qualitative evaluation of the angiogenic effect. Using the same technique,<sup>7</sup>

latex was injected into the arterial graft and the results were compared visually with our previous results.

#### Statistical Analysis

Grouped data are expressed as mean  $\pm$  SD of  $n$  observations, where  $n$  denotes the number of animals per group. All compilations and  $t$  tests with unequal variance were calculated using Microsoft Excel. A  $p$  value less than 0.05 was considered significant.

#### RESULTS

Clinically, rats treated with pulsed magnetic fields experienced no ill effects. No animals developed infection, and no animals required antibiotic therapy. During the experiment, the 8-week-old animals were noted to have gained  $161 \pm 48$  g (mean  $\pm$  SD), and the 12-week-old animals had gained  $212 \pm 38$  g. The average weight gain per week (group 1,  $20.8 \pm 5.2$  g; group 2,  $19.4 \pm 7.0$  g; group 3,  $17.5 \pm 2.1$  g; group 4,  $17.8 \pm 3.8$  g) and the average weight at time of the first surgical procedures (group 1,  $385 \pm 41$  g; group 2,  $377 \pm 45$  g; group 3,  $366 \pm 48$  g; group 4,  $346 \pm 36$  g) were not statistically different among the four groups. None of these animals suffered any burns, nor did any animal die during the course of the treatment.

In Table I, the results of mean percentage flap survival with SD and  $p$  values are summarized. Evaluating the effects of pulsed magnetic fields on skin flap survival of the composite flap, it was noted that at 8 weeks after creation of the arterial loop, a flap based only on the transferred vessel did not survive unless it was treated with pulsed magnetic fields. The control group ( $10.69 \pm 15.32$ ) had statistically significant skin flap failure, whereas the experimental group ( $94.89 \pm 7.02$ ) had significant skin flap survival (Fig. 2). Although the variance in the control group was greater than that in the experimental group, this had no effect

TABLE I  
Pulsed Magnetic Fields Treatment Results

Group	No. of Rats	Duration (weeks)	PME Treatment	Mean Flap Survival* (%)	$p$
1 (control)	16	8	No	$10.69 \pm 15.32$	<0.001
2 (experimental)	14	8	PMF	$94.89 \pm 7.02$	
3 (control)	5	12	No	$82.20 \pm 18.74$	0.39
4 (experimental)	8	12	PMF	$88.96 \pm 8.76$	

PMF, pulsed magnetic fields.

\* Mean flap survival is expressed as mean  $\pm$  SD.



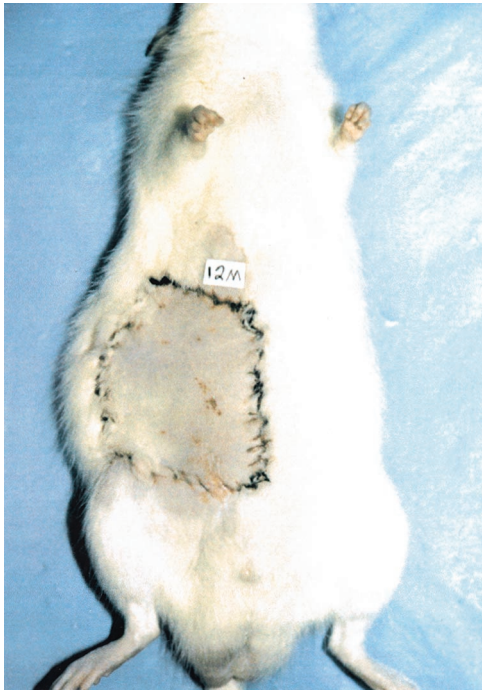


FIG. 2. The groin flap in an 8-week pulsed magnetic fields-treated animal at postoperative day 5 showing full survival after being elevated and replaced in its bed. The original blood supply from the epigastric vessel is no longer intact.

on the statistical significance of  $p < 0.001$ . After 12 weeks, flap survival was nearly as good in the control group ( $82.20 \pm 18.74$ ) as in the pulsed magnetic fields-treated group ( $88.96 \pm 8.76$ ). Here, too, the variance was greater in the control group than in the experimental group but had no effect on the statistical significance ( $p = 0.39$ ).

#### DISCUSSION

Our experimental findings support our previous results: pulsed magnetic fields affect a transferred arterial loop by causing neovascularization. We clearly demonstrate that the composite flap is able to survive purely on circulation from this transferred arterial loop when the dominant arterial vessel is divided (Fig. 2). The ability to substitute the existing arterial system by a preplanned vessel leads to speculation as to whether random areas of skin can be converted to free-flap sites, if arterial loops are placed and then treated with pulsed magnetic fields. Clinical evidence for this is suggested by Khouri et al.,<sup>9</sup> who were able to transfer expanded supraclavicular skin as an island pedicle flap based on an induced vascular pedicle by 10 to 12 weeks. Theile et al.<sup>10</sup> showed a time-dependent sprouting of vessels

to bridge a gap of excised artery that by 14 days was able to support a flap of tissue based on the redeveloped vessels.

The importance of treatment with pulsed magnetic fields is the ability to accelerate the angiogenic process to have enough vascularization to support the composite flap. At 8 weeks, there is an enormous discrepancy between the treated and control groups (Figs. 3 and 4). Without pulsed magnetic field therapy, flap survival dropped to 11 percent of the treated group. By 12 weeks, the pulsed magnetic fields group and the control groups have similar flap survival. This follows our original study that demonstrated quantifiable neovascularization in the control loops by 12 weeks, but a negligible amount by 8 weeks.<sup>7</sup> Pulsed magnetic fields allow for accelerated maturation of the composite flap, resulting in superior skin flap survival over that of the control group.

Venous congestion is well known to be a cause for delayed failure of free-tissue transfers; therefore, it is hardly surprising that venous outflow is essential for our flap survival. Previous work resulted in complete flap loss in all animals when the superficial inferior epigastric vein was ligated. Future experiments will need to address the effects of pulsed magnetic fields on a transplanted vein and ultimately test the idea that a complete inflow and outflow system can be formed to support any random selection of tissue. The ability to create an arteriovenous system in a relatively short time may help overcome the current limitations of tissue engineering.<sup>11</sup>

Since the concept of angiogenesis was popularized by Folkman et al.,<sup>12-14</sup> there has been a

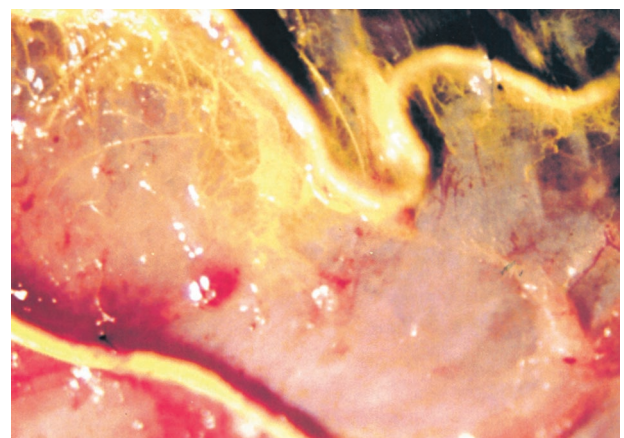


FIG. 3. High magnification of an 8-week pulsed magnetic fields-treated rat tail arterial loop showing intense neovascularization.

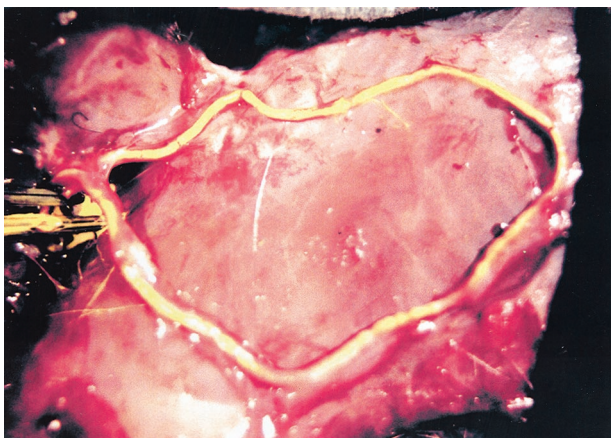


FIG. 4. Eight-week control rat tail arterial loop showing the entire loop with a paucity of new blood vessel formation.

tremendous amount of research in this field. The use of angiogenic factors, such as platelet-derived growth factor, vascular endothelial growth factor, or basic fibroblastic growth factor, both clinically and experimentally, has shown a general increase in angiogenesis. Application to a skin flap at the time of creation or postoperatively, injected locally, given systemically, or applied topically, and in all the countless ways being investigated, results in a consistent acceleration to the normal healing properties.<sup>15-17</sup> The disadvantage of using these products is the limited U.S. Food and Drug Administration approval for clinical use and the cost, storage, and production of these products. Pulsed magnetic fields, on the other hand, are relatively simple to apply, and have the advantage of being used externally. Clinically, the full potential of pulsed magnetic fields is still unexplored.

#### CONCLUSIONS

Successful flap creation could be achieved at 8 weeks if animals are treated with pulsed magnetic fields. Control animals that had flaps created at 8 weeks had near complete flap failure. Our results clearly demonstrate that with the use of pulsed magnetic fields, a transplanted arterial loop can sustain a composite flap rendered random with 8 weeks of treatment. Expanding on previous results, we have shown that, in addition to increasing angiogenesis in an arterial loop in a time-dependent manner, treatment with pulsed magnetic fields allows for early maturation of the composite flap. The major advantages of this modality are that it is easy to use and that the energy is applied transcutaneously.

Berish Strauch, M.D.  
1625 Poplar Street  
Suite 200  
Bronx, N.Y. 10461  
bstrauch@Montefiore.org

#### REFERENCES

1. Glazer, P. A., Heilmann, M. R., Lotz, J. C., and Bradford, D. S. Use of electromagnetic fields in spinal fusion: A rabbit model. *Spine* 22: 2351, 1997.
2. Bassett, C. A. L., Mitchell, S. N., and Schink, M. M. Treatment of therapeutically resistant non-unions with bone grafts and pulsing electromagnetic fields. *J. Bone Joint Surg. (Am.)* 64: 1214, 1982.
3. Darendeliler, M. A., Darendeliler, A., and Sinclair, P. M. Effects of static magnetic and pulsed magnetic fields on bone healing. *Int. J. Adult Orthodon. Orthognath. Surg.* 12: 43, 1997.
4. Yen-Patton, G. P., Patton, W. F., Beer, D. M., and Jacobson, B. S. Endothelial cell response to pulsed electromagnetic fields: Stimulation of growth rate and angiogenesis in vitro. *J. Cell Physiol.* 134: 37, 1988.
5. Markov, M. S. Electric current and electromagnetic field effects on soft tissue: Implications for wound healing. *Wounds* 7: 94, 1995.
6. Greenough, C. G. The effects of pulsed electromagnetic fields on blood vessel growth in the rabbit ear chamber. *J. Orthop. Res.* 10: 256, 1992.
7. Roland, D., Ferder, M., Kothuru, R., et al. Effects of pulsed magnetic energy on a microsurgically transferred vessel. *Plast. Reconstr. Surg.* 105: 1371, 2000.
8. Strauch, B., and Murray, D. E. Transfer of composite graft with immediate suture anastomosis of its vascular pedicle measuring less than 1 mm in external diameter using microsurgical techniques. *Plast. Reconstr. Surg.* 40: 325, 1967.
9. Khouri, R. K., Ozbek, M. R., Hruza, G. J., and Young, V. L. Facial reconstruction with prefabricated induced expanded (PIE) supraclavicular skin flaps. *Plast. Reconstr. Surg.* 95: 1007, 1995.
10. Theile, D. R. B., Kane, A. J., Romeo, R., et al. A model of bridging angiogenesis in the rat. *Br. J. Plast. Surg.* 51: 243, 1998.
11. Cassell, O. C. S., Hofer, S. O. P., Morrison, W. A., and Knight, K. R. Vascularisation of tissue-engineered grafts: The regulation of angiogenesis in reconstructive surgery and in disease states. *Br. J. Plast. Surg.* 55: 603, 2002.
12. Folkman, J. Tumor angiogenesis: Therapeutic implications. *N. Engl. J. Med.* 285: 1182, 1971.
13. Folkman, J., Merler, E., Abernathy, C., and Williams, G. Isolation of a tumor factor responsible for angiogenesis. *J. Exp. Med.* 133: 275, 1971.
14. Folkman, J., and Klagsbrun, M. Angiogenic factors. *Science* 235: 442, 1987.
15. Hickey, M. J., Wilson, Y., Hurley, J. V., and Morrison, W. A. Mode of vascularization of control and basic fibroblast growth factor-stimulated prefabricated skin flaps. *Plast. Reconstr. Surg.* 101: 1296, 1998.
16. Li, Q. F., Reis, E. D., Zhang, W. X., et al. Accelerated flap prefabrication with vascular endothelial growth factor. *J. Reconstr. Microsurg.* 16: 45, 2000.
17. Haws, M. J., Erdman, D., Bayati, S., et al. Basic fibroblast growth factor induced angiogenesis and prefabricated flap survival. *J. Reconstr. Microsurg.* 17: 39, 2001.